

DOI <http://doi.org/10.17816/2313-8726-2021-8-2-101-108>



Vaginal extirpation of the uterus using implants made of titanium silk to prevent recurrence of the disease

Anatoliy I. Ishchenko^{1,2}, Tat'yana V. Gavrilova², Anton A. Ishchenko¹, Oksana Yu. Gorbenko¹, Teya A. Dzhibladze¹, Irina D. Khokhlova¹, Leonid S. Aleksandrov¹

¹I.M. Sechenov First Moscow State Medical University, Moscow, Russian Federation;

²V.F. Snegirev Clinic of Obstetrics and Gynecology, Moscow, Russian Federation

ABSTRACT

INTRODUCTION: The frequency of post-hysterectomy prolapse of the vaginal dome reaches 43% in patients after surgical treatment for complete uterine prolapse.

AIM: improving the effectiveness of surgical treatment with titanium mesh implants in pre- and postmenopausal patients with complete uterine prolapse.

MATERIALS AND METHODS: The study involved 21 patients with complete uterine prolapse who underwent the proposed new method of transvaginal surgical prevention of post-hysterectomy prolapse of the vaginal dome. The result of surgical treatment was evaluated by analyzing the data of vaginal examination and ultrasound.

RESULTS: Patients were observed for 2 years — after 1, 6, 12 and 24 months. Analysis of vaginal examination and ultrasound data showed no displacement of the vaginal dome, pelvic organs and deformation of titanium implants. There were no mesh-associated complications during follow-up.

CONCLUSIONS: The use of the developed surgical method for the correction of post-hysterectomy prolapse of the vaginal dome with the use of implants made of titanium silk is a reliable tool that provides anatomical efficiency in pre- and postmenopausal patients.

Keywords: genital prolapsed; transvaginal surgical prevention of post-hysterectomy prolapse of the vaginal dome; mesh endoprotheses.

To cite this article:

Ishchenko AI, Gavrilova TV, Ishchenko AA, Gorbenko OYu, Dzhibladze TA, Khokhlova ID, Aleksandrov LS. Vaginal extirpation of the uterus using implants made of titanium silk to prevent recurrence of the disease. *V.F. Snegirev Archives of Obstetrics and Gynecology, Russian journal.* 2021;8(2):101–108. (In Russ). DOI: <http://doi.org/10.17816/2313-8726-2021-8-2-101-108>

Received: 25.02.2021

Accepted: 20.03.2021

Published: 25.05.2021

DOI <http://doi.org/10.17816/2313-8726-2021-8-2-101-108>

Влагалищная экстирпация матки с использованием имплантатов из титанового шёлка для профилактики рецидива заболевания

А.И. Ищенко^{1,2}, Т.В. Гаврилова², А.А. Ищенко¹, О.Ю. Горбенко¹,
Т.А. Джигладзе¹, И.Д. Хохлова¹, Л.С. Александров¹

¹Первый Московский государственный медицинский университет им. И.М. Сеченова, Москва, Российская Федерация

²Клиника акушерства и гинекологии им. В.Ф. Снегирёва, Москва, Российская Федерация

Введение. Частота постгистерэктомического пролапса купола влагалища достигает 43% у пациенток после хирургического лечения по поводу полного выпадения матки.

Цель работы — повышение эффективности хирургического лечения с применением титановых сетчатых имплантатов у пациенток пре- и постменопаузального возраста с полным выпадением матки.

Материал и методы. В исследовании приняла участие 21 пациентка с полным выпадением матки, которым выполнен предложенный нами новый способ трансвагинальной хирургической профилактики постгистерэктомического пролапса купола влагалища. Оценивали результат оперативного лечения путём анализа данных влагалищного исследования и УЗИ.

Результаты. Наблюдали пациенток в течение 2 лет — через 1, 6, 12 и 24 мес. Анализ данных влагалищного исследования и УЗИ показал отсутствие смещения купола влагалища, тазовых органов и деформации титановых имплантатов. Mesh-ассоциированных осложнений за время наблюдения не отмечено.

Заключение. Использование разработанного хирургического способа коррекции постгистерэктомического пролапса купола влагалища с применением имплантатов из титанового шёлка — надёжное пособие, обеспечивающее высокую анатомическую эффективность у пациенток пре- и постменопаузального возраста.

Ключевые слова: генитальный пролапс; трансвагинальная хирургическая профилактика постгистерэктомического пролапса купола влагалища; сетчатые эндопротезы.

Как цитировать:

Ищенко А.И., Гаврилова Т.В., Ищенко А.А., Горбенко О.Ю., Джигладзе Т.А., Хохлова И.Д., Александров Л.С. Влагалищная экстирпация матки с использованием имплантатов из титанового шёлка для профилактики рецидива заболевания // Архив акушерства и гинекологии им. В.Ф. Снегирёва. 2021. Т. 8, № 2. С. 101–108. DOI: <http://doi.org/10.17816/2313-8726-2021-8-2-101-108>

Genital prolapse is a pathology that leads to the descent of the internal genital organs and adjacent organs (urinary bladder and rectum). Ptosis and prolapse of the internal genital organs often lead to disability because of a violation of the relative position of the organs and their functions, thereby reducing patients' quality of life. This problem is still relevant; however, it remains a complex unresolved problem and continues to arouse the interest of gynecological surgeons and physicians of related specialties: urologists and coloproctologists [1, 2].

Based on world literature data, the incidence of pelvic organ prolapse varies within 4.5%–30%. Prolapse of the internal genitalia reaches 28%–39% in the structure of gynecological diseases, and it ranks third after benign diseases of the pelvic organs and endometriosis in the structure of planned indications for surgical treatment [3].

The only effective treatment for genital prolapse is surgery. Despite various surgical techniques and their modifications, the number of relapses of pelvic organ prolapse is not reduced. According to various authors, the number of relapses reaches 33%–61% [4, 5].

A common and complex form of genital prolapse is posthysterectomic prolapse of the vaginal vault, which occurs because of the disorder of the ligamentous apparatus architectonics, namely, the intersection of the sacro-uterine and cardinal ligaments (Level I according to DeLancey) during hysterectomy [6]. According to national researchers, total hysterectomy is the common surgery in surgical gynecology, and it occurs in 38.2% of cases [7, 8]. Despite the many surgical techniques in preventing posthysterectomic prolapse of the vaginal vault, including the use of synthetic endoprostheses, the frequency of total hysterectomy reaches 43%.

At present, synthetic implants are used often; however, despite attempts to increase biocompatibility with patient tissues, the problem remains unresolved because of the development of mesh-associated complications [9].

Relapses of pelvic organ prolapse and mesh-associated complications induce the necessity to search new materials and improve treatment methods for severe forms of genital prolapse. Thus, our study focuses on the development of a new surgical method for the treatment of complete uterine prolapse, the prevention of posthysterectomic prolapse of the vaginal vault using modern high-tech titanium endoprostheses made of titanium silk, and the evaluation of its effectiveness in pre- and postmenopausal patients with complete uterine prolapse.

This study aimed to improve the efficiency of surgical treatment using titanium mesh implants in pre- and postmenopausal patients with complete uterine prolapse.

MATERIALS AND METHODS

This study was conducted in 2018–2020 in the Clinic of Obstetrics and Gynecology, which was named after

V.F. Snegiryov — clinical base of the Obstetrics and Gynecology Department No. 1 of N.V. Sklifosovsky Institute of Clinical Medicine of Sechenov University.

Our study included 21 pre- and postmenopausal patients with complete uterine prolapse. The study group was formed by using continuous thematic sampling. The inclusion criteria were as follows: complete prolapse of the uterus and consent of patients for surgical treatment using titanium endoprostheses (protocol of the Local Ethical Committee of Sechenov University dated October 7, 2020, No. 28-20).

The exclusion criteria were as follows: purulent-inflammatory diseases of the pelvic organs; malignant lesions of the pelvic organs; severe adhesions in the pelvis; and congenital or acquired deformities of the pelvic bones and/or hip joints, which do not allow the surgery to be performed by transvaginal access.

Preoperative examination of patients included the collection of complaints, anamnesis, an objective examination, gynecological and rectal examinations, instrumental and laboratory methods based on indications, and consultations of other specialists (cardiologist, pulmonologist, endocrinologist, and urologist).

Analyzing the data of patients' anamnesis, we found out the nature and time of the manifestation of complaints, the stages of development of the underlying disease, the features of heredity, extragenital pathology, and parameters of menstrual and reproductive functions. The nature of previous gynecological diseases and surgical interventions was also considered.

Vaginal examination determined the location of the internal genital organs (vaginal and uterine walls), and their relationship to the vaginal orifice.

Rectal examination allows the determination of the degree of the posterior vaginal wall prolapse, identification of a rectocele, and differentiation of the latter from an enterocele.

When determining the degree of pelvic prolapse, we were guided by the Pelvic Organ Prolapse Quantification (POP-Q) system classification.

Ultrasound examination of the pelvic organs was performed using the Toshiba Aplio device (Japan), equipped with multifrequency transvaginal and convex sensors.

The obtained data were processed by standard methods of descriptive and variational statistics using Student's *t*-test.

The mean age of patients with complete uterine prolapse was 62.7 years. In addition, 41.2% of patients were aged 52–59 years, 35.3% were 60–69 years old, and 23.5% were 70–79 years old. Two patients were in the premenopausal period, and the remaining 19 patients were in the postmenopausal period.

Pelvic organ prolapse was characterized by a variety of patient complaints. In 100% of cases, patients noted discomfort, a sensation of a foreign body in the vagina and in the perineum, thereby experiencing awkwardness and unpleasant and often painful sensations when moving. Drawing and

aching pains in the lower abdomen and in the lumbosacral region, frequent urge to urinate, stress urinary incontinence, and a feeling of incomplete emptying of the bladder were noted by 82.3%, 44.9%, 56.7%, and 19.1% of women, respectively. Constipation occurred in 39.6% of patients; 37.1% of sexually active women noted dyspareunia and the impossibility of a full sexual life. According to A.A. Popov, functional disorders of adjacent organs could occur in 85% of patients with genital prolapse [10].

For the first time, a feeling of discomfort in the vagina was noted in 3, 11, and 7 patients approximately 21, 6–10, and 5 years ago, respectively. The symptoms progressed as the degree of prolapse of the internal genital organs increased.

Family history data were evident on the hereditary nature of the disease because genital prolapse was present in mothers in every fourth observation and in maternal grandmothers in every seventh patient.

In the structure of extragenital pathology, diseases of the cardiovascular system such as hypertension and coronary heart disease are found in 71.9% and 43.6% of patients. Among the pathologies of the gastrointestinal tract, 31.3% of women had chronic gastritis, 20.7% had chronic cholecystitis and cholelithiasis, 73.1% had varicose veins, 12.5% had hypermobility and dislocations of the joints, 32.3% had arthrosis of large joints and osteochondrosis of various parts of the spine, and 13.6% had hernias of various localization, which may indicate connective tissue dysplasia.

Menstrual function and the time of onset of menopause had no features, and they were comparable in all subjects. Thus, the average age of menarche was 12.4 ± 1.3 years, and the age of menopause was 52.8 ± 2.9 years.

Analysis of the obstetric anamnesis revealed that 66.9% of patients had 1–2 term deliveries in the past, and 33.1% had 3–4 term deliveries through the natural birth canal. Injuries of the perineum and vagina during childbirth were noted in 78.4% of women, which is a predisposing factor affecting the development of prolapse.

Among gynecological diseases, 8 patients had a history of hysteromyoma, 10 had salpingo-oophoritis, 9 had polyps and endometrial hyperplasia, and 3 had benign ovarian tumors.

During vaginal examination, the patients showed a hernial sac that extended beyond the area of the vaginal orifice. The internal genital organs were located in a hernial sac, the walls of which were the anterior and posterior vaginal walls. The sac was reduced depending on the size.

Ultrasound showed a decrease in the height of the tendon center of the perineum less than 1 cm, diastasis of the muscles in the area of the tendon center, and a decrease in the width of the muscle bundles of the bulbocavernosus muscle (less than 1.5 cm). The uterine cervix and body were determined in the hernial sac outside the vaginal orifice. In 29.3% of cases, elongation of the cervix up to 5–8 cm was noted. Deformation of the bladder contour, dislocation of the

urethrovaginal segment, and deformation of the contours of the anterior wall of the rectum were visualized.

Complete uterine prolapse indicated surgical treatment in all patients (Grade IV genital prolapse based on the POP-Q classification).

The common surgical interventions for strengthening the vaginal vault include sacrospinal colpopexy with or without mesh implants, sacrospinous colpopexy, and McCall culdoplasty [11–14]. The commonly used colpopexy is the use of polypropylene mesh implants. By reducing the risk of recurrence of genital prolapse, mesh-associated complications occur, which lead to a decrease in the effectiveness and safety of surgical treatment.

Based on the data of domestic and foreign researchers, the frequency of mesh-associated and general surgical intraoperative complications varies within 10%–33% [15–19].

Following FDA's notification of the discontinuation of implantable transvaginal meshes in the US market, the development of titanium implants for use in pelvic prolapse has become relevant. In particular, titanium silk endoprosthesis (VT1-00 alloy, titanium content 99.9%) is represented by an elastic mesh made of a monofilament thread. Titanium has high inertness, exceptional strength, high plasticity, and pronounced adhesion to the surface of the surgical wound. Titanium easily takes and holds a given shape and improves the integration of the material because of the rapid process of its settlement with fibroblasts and osteoblasts, and it has a high rate of penetration of biological fluids into the implant and tension properties (material relaxation). Protein vitronectin, which is an important initiator of the formation of connective tissue, is deposited on titanium silk (Table 1). Unlike polypropylene implants, which undergo partial destruction after 5–6 years that leads to deformation of the endoprosthesis, dyspareunia, and chronic pelvic pain syndrome, titanium implants do not undergo structural changes [2, 20].

Surgical technique

We used transvaginal access and spinal anesthesia to perform surgical treatment.

The scope of surgery includes vaginal hysterectomy, sacrospinal transobturator crossed colpopexy using titanium mesh implants, anterior colporrhaphy, and colpoperineolevatoroplasty. The steps of surgery are as follows:

Vaginal hysterectomy was performed on the basis of the Mayo technique leaving sacro-uterine and cardinal ligaments extraperitoneally on both sides (stage I).

The round ligaments of the uterus and stumps of the appendages (the uterine ends of the tubes and ligaments of the ovaries) were sutured together with a continuous suture, using slowly absorbable ligatures, connecting the ligaments into a single ligamentary monoblock. Sacro-uterine and cardinal ligaments were fixed to the monoblock.

After peritonization, channels were formed toward the ischial spines and sacrospinous ligaments. Departing 1.5–2 cm from the ischial spines, a titanium fixator with

a ligature was inserted into the thickness of the sacrospinous ligament. During device installation (titanium fixator), a non-absorbable fixing thread was passed through the holes in both protrusion lugs; the distal end of the bent guide was passed inside the fixator and fixed. Both ends of the thread were fixed on the handle of the guide. The conductor together with the fixator was passed into the thickness of the tissues and brought to the right sacrospinous ligament approximately 2 cm medially to the internal spine, and then it was inserted into the ligament to a depth of 1 cm. The conductor was disconnected from the fixator by rotation around its axis and removed in reverse. Pulling the ends of the ligature (ligature 1), the strength of the fixator set was checked. Similarly, the second fixator with a thread was passed and fixed in the region of the left sacrospinous ligament (ligature 2). The free ends of the threads (ligatures 1 and 2) were fixed to the sacrospinous ligaments prepared by using narrow ribbon-like mesh titanium implants alternately on both sides.

The free end of the titanium implant, fixed to the left sacrospinous ligament, was passed through the membrane and muscles of the right obturator foramen of the pelvis using a conductor under the control of the index finger, and then it was brought out into the right inguinal-femoral fold at the level of the clitoris with an incision on the skin approximately 0.7 cm (stage II). The second titanium implant was fixed to the right sacrospinous ligament and removed through the left obturator foramen.

Under visual control, the peripheral ends of titanium tape-like implants, which were brought into the region of the inguinal-femoral folds, were tightened, providing stable support for the vaginal dome. By pulling on the ends of the titanium tapes, which were brought out through the obturator membranes, the vaginal vault was fixed as high as possible in the small pelvis (stage II).

Afterward, the mesh implants were sutured with two to three slowly absorbable ligatures to the monoblock (sacro-uterine-cardinal complex), which were simultaneously sutured together (Fig.).

Anterior colporrhaphy and colpoperineolevatoroplasty were performed using the usual technique (stage III).

After 1, 6, 12, and 24 months, patients were followed up to 2 years. The result of surgical treatment was evaluated by analyzing the data of vaginal examination and ultrasound. Genital prolapse stage II was considered as relapse based on the POP-Q classification.

RESULTS AND DISCUSSION

The course of the intraoperative, early (up to 30 days) and late (more than 30 days) postoperative period, was analyzed.

The duration of the surgery varied within 75–85 min, and the volume of intraoperative blood loss was 150–250 mL. The bed day was approximately 5–7 days. No intraoperative

Table 1. Material specifications of cuttable titanium silk

Parameter	Value
Thread thickness, μm	40–60
Mesh thickness, μm	180–250
Inactivity in human tissues	Absolute
Potential of cutting	Yes
Porosity, %	96
Elasticity, %	40–80
Surface density, g/m^2	25–55
Mesh cell size, mm	0.5–2
Repeated sterilization	Possible
Adhesion to postoperative wound tissues	High
Resistance to aggressive environment, antiseptics and microbial enzymes	High

complications (bleeding requiring transfusion of blood components and injury to adjacent organs) were found. In the early postoperative period, pain in the perineal region was noted in 13 (61.9%) patients. When taking non-steroidal anti-inflammatory drugs, the pain was arrested. Hematomas of the paravesical region of the vagina of 30–50 mL in volume were diagnosed in two (9.5%) patients. Surgical treatment of hematomas was not required, but they were resolved through antibacterial anti-inflammatory therapy. Urinary retention occurred in one (4.8%) patient, which required 1 mL of 0.05% Prozerin two times a day intramuscularly for 3 days.

Observations in the delayed postoperative period (1–24 months) showed 100% efficiency of the surgical method. Subjectively, the patients were satisfied with the results of surgical treatment. Vaginal examination revealed that the vaginal vault was high, and the prolapse of the anterior and

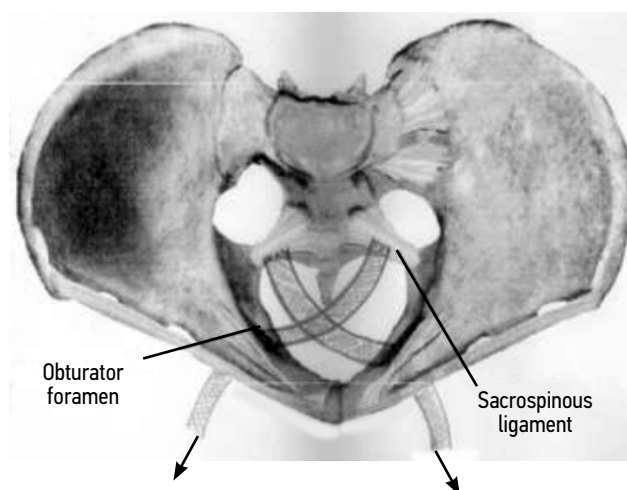


Fig. Fixation of mesh titanium implants to a ligamentous monoblock (sacro-utero-cardinal complex).

posterior vaginal walls at rest and during straining was not observed. Based on the ultrasound data, the vaginal vault was at or above the level of pubic symphysis, and deformation and displacement of the titanium implants were not observed. A decrease in levator diastasis and an increase in the tendon center were noted. No relapses were registered during the entire observation period.

CONCLUSION

The frequency of posthysterectomic vaginal vault prolapse in pre- and postmenopausal patients led to the development of a new method for surgical prevention. The method developed for extraperitoneal transvaginal colpexy with a cardinal–sacral–uterine ligamentary monoblock and sacrospinal transobturator crossed colpexy using titanium endoprotheses was reliable and highly efficient. The use of titanium ligature fixators in soft tissues, namely, the sacrospinal ligaments, reduced trauma by minimizing the dissection of soft tissues to access the ligaments, thereby reducing the duration of the surgery and blood loss. The

small size and volume of titanium implants reduced the risk of intra- and postoperative complications.

Thus, the developed method for the surgical prevention of posthysterectomic prolapse of the vaginal vault by using modern titanium mesh endoprotheses and strengthening the vaginal vault with a cardinal–sacral–uterine ligamentary monoblock can be used with high efficiency to reduce the frequency of relapse.

ADDITIONAL INFO

Author contribution. All the authors made a significant contribution to the development of the concept, research and preparation of the article, read and approved the final version before publication.

Competing interests. The authors declare that they have no competing interests.

Funding source. This study was not supported by any external sources of funding.

Ethics approval. This study was approved by the Local Ethical Committee of the I.M. Sechenov First Moscow State Medical University (No. 28-20 of 07.10.2020).

REFERENCES

1. Kulakov VI, Adamyan LV, Askol'skaya SI. Women's health and hysterectomy. In: *Materials of the International Congress «Endoskopiya v diagnostike, lechenii i monitoringe zhenskikh boleznei»*. Moscow: Santori; 2000. P. 224–237. (In Russ).
2. Baggish MS, Karram MM. *Atlas of pelvic Anatomy and Gynecologic Surgery*. 4th ed. Eng: Elsevier; 2015. 1408 p.
3. Luk'yanova DM, Smol'nova TYu, Adamyan LV. Modern molecular-genetic and biochemical predictors of genital prolapsed. *Problemy reproduksii*. 2016;(4):8. (In Russ).
4. Bezhnar' VF, Bogatyreva EV. Methods of surgical treatment of rectocele in women with omission and prolapse of the internal genitals. *Zhurnal akusherstva i zhenskikh boleznei*. 2009;LVIII(2):16–22. (In Russ).
5. Malkhasyan VA, Kasyan GR, Sumerova NM. Anatomical and functional results of surgical correction of pelvic organ prolapse using transvaginal implantation of a synthetic prosthesis: a prospective study in 105 patients. *Rossiiskii vestnik akushera-ginekologa*. 2012;1:70–74. (In Russ).
6. Hirsch HA, Kezer O, Ikke FA. *Operative gynecology. Atlas*. Transl. from English. Moscow: GEOTAR-Media; 2004. 649 p. (In Russ).
7. Frinovskii VS. Mayo surgery for uterine prolapse in elderly women and its long-term results. *Akusherstvo i ginekologiya*. 1941;(5):32–35. (In Russ).
8. Shalaev ON. *Khirurgicheskoe lechenie dobrokachestvennykh zabolovaniy matki i genital'nogo prolapsa s ispol'zovaniem vlagalishchnogo operativnogo dostupa* [dissertation]. Moscow; 2004. Available from: <https://elibrary.ru/item.asp?id=16170836>. (In Russ).
9. Patel H, Ostergard DR, Sternschuss G. Polypropylene mesh and the host response. *Int Urogynecol J*. 2012;23(6):669–679.
10. Popov AA. *Sovremennye aspekty diagnostiki, klassifikatsii i khirurgicheskogo lecheniya opushcheniya i vypadeniya zhenskikh polovykh organov* [dissertation]. Moscow; 2001. Available from: https://rusneb.ru/catalog/000200_000018_RU_NLR_bibl_408447/. (In Russ).
11. Popov AA, Kashina EA, Buyanova SN, et al. Surgical treatment of patients with omission and prolapse of the internal genitals and prevention of omission of the vaginal dome after hysterectomy. *Rossiiskii vestnik akushera-ginekologa*. 2006;6(4):66–71. (In Russ).
12. Tikhomirov AL, Bagaev VM, Khodzhaev GG. Treatment of omission and prolapse of the vagina and uterus. In: *Collection of scientific works of employees of the Central Clinical Hospital of the Ministry of Railways*. Moscow. 1999;(4):502–510. (In Russ).
13. Malinowski A, Pawlowski T, Maciolek-Blew-Nielwska G, Augustyniak T. Sacrospinous ligament vaginal vault fixation-method, results and a one-year follow up in 10 patients. *Ginekol Pol*. 2004;75(9):713–719.
14. Fattou B, Dwyer PL, Achtari C, Tan PK. Bilateral extraperitoneal uterosacral vaginae vault suspension: a 2-year follow-up longitudinal case series of 123 patients. *Int Urogynecol J Pelvic Floor Dysfunct*. 2009;20(4):427–434. DOI: 10.1007/s00192-008-0791-8
15. Chechneva MA, Barto RA, Burykina TS, Krasnopol'skaya IV, Obramyat KN. Modern ideas about the pathogenesis, diagnosis and methods of correction of genital prolapse and its complications (literature review). *Patogenez*. 2014;12(4):4–9. (In Russ).
16. Abed H, Rahn DD, Lowenstein L, et al. Incidence and management of graft erosion, wound granulation, and dyspareunia following vaginal prolapse repair with graft materials: a systematic review. *Int Urogynecol J*. 2011;22(7):789–798.
17. Blandon RE, Gebhart JB, Trabuco EC, Klingele CJ. Complication from vaginally placed mesh in pelvic reconstructive surgery. *Int Urogynecol J*. 2009;20(5):523–531.
18. Dandolu V, Akiyama M. Mesh complications and failure rates after transvaginal mesh repair compared with abdominal or laparoscopic sacrocolpopexy and to native tissue repair in treating apical prolapsed. *Int Urogynecol J*. 2017;28(2):215–222.

19. Sung VW, Rogers RG, Schaffer JI, et al. Graft use in transvaginal pelvic organ prolapse repair: a systematic review. *Obstet Gynecol*. 2008;112(5):1131–1142.

20. Khodakov VV, Zabrodin VV, Zabrodin EV, Vaseva ON. Immediate and long-term results of surgical treatment of inguinal hernias using mesh titanium endoprostheses. *Meditsinskii zhurnal*. 2018;(7):93–101. (In Russ). DOI: 10.25694/URMJ.2018.04.132

СПИСОК ЛИТЕРАТУРЫ

1. Кулаков В.И., Адамян Л.В., Аскольская С.И. Здоровье женщины и гистерэктомия. В кн.: Материалы Международного конгресса «Эндоскопия в диагностике, лечении и мониторинге женских болезней». Москва : Сантори, 2000. С. 224–237.
2. Baggish M.S., Karram M.M. Atlas of Pelvic Anatomy and Gynecologic Surgery. 4th ed. Eng. : Elsevier, 2015. 1408 p.
3. Лукьянова Д.М., Смольнова Т.Ю., Адамян Л.В. Современные молекулярно-генетические и биохимические предикторы генитального пролапса // Проблемы репродукции. 2016. № 4. С. 8.
4. Беженарь В.Ф., Богатырева Е.В. Методы хирургического лечения ректоцеле у женщин при опущении и выпадении внутренних половых органов // Журнал акушерства и женских болезней. 2009. Т. LVIII, № 2. С. 16–22.
5. Малхасян В.А., Касян Г.Р., Сумерова Н.М. Анатомические и функциональные результаты хирургической коррекции пролапса тазовых органов с помощью трансвагинальной имплантации синтетического протеза: проспективное исследование у 105 пациенток // Российский вестник акушера-гинеколога. 2012. Т. 1. С. 70–74.
6. Хирш Х.А., Кезер О., Икле Ф.А. Оперативная гинекология. Атлас. Пер. с англ. Москва : ГЭОТАР-Медиа, 2007. 649 с.
7. Фриновский В.С. Операция Мейо при выпадениях матки у пожилых женщин и отдаленные ее результаты // Акушерство и гинекология. 1941. № 5. С. 32–35.
8. Шалаев О.Н. Хирургическое лечение доброкачественных заболеваний матки и генитального пролапса с использованием влагалищного оперативного доступа. Дис. ... д-ра мед. наук. Специальность 14.00.01. Москва, 2004. Режим доступа: <https://elibrary.ru/item.asp?id=16170836>. Дата обращения: 06.03.2021.
9. Patel H., Ostergard D.R., Sternschuss G. Polypropylene mesh and the host response // *Int Urogynecol J*. 2012. Vol. 23, N 6. P. 669–679.
10. Попов А.А. Современные аспекты диагностики, классификации и хирургического лечения опущения и выпадения женских половых органов. Дис. ... д-ра мед. наук. Москва, 2001. Режим доступа: https://rusneb.ru/catalog/000200_000018_RU_NLR_bibl_408447/. Дата обращения: 06.03.2021.
11. Попов А.А., Кашина Е.А., Буянова С.Н., и др. Хирургическое лечение больных с опущением и выпадением внутренних поло-

вых органов и профилактика опущения купола влагалища после гистерэктомии // Российский вестник акушера-гинеколога. 2006. Т. 6, № 4. С. 66–71.

12. Тихомиров А.Л., Багаев В.М., Ходжаев Г.Г. Лечение опущения и выпадения влагалища и матки // Сборник научных трудов сотрудников ЦКБ МПС. Москва : 1999. № 4. С. 502–510.

13. Malinowski A., Pawlowski T., Maciolek-Blew-Nielwska G., Augustyniak T. Sacrospinous ligament vaginal vault fixation-method, results and a one-year follow up in 10 patients // *Ginekol Pol*. 2004. Vol. 75, N 9. P. 713–719.

14. Fattouh B., Dwyer P.L., Ahtari C., Tan P.K. Bilateral extraperitoneal uterosacral vaginae vault suspension: a 2-year follow-up longitudinal case series of 123 patients // *Int Urogynecol J Pelvic Floor Dysfunct*. 2009. Vol. 20, N 4. P. 427–434.

DOI: 10.1007/s00192-008-0791-8

15. Чечнева М.А., Барто П.А., Бурыкина Т.С., Краснопольская И.В., Обрамчат К.Н. Современные представления о патогенезе, диагностике и способах коррекции пролапса гениталий и его осложнений (обзор литературы) // Патогенез. 2014. Т. 12, № 4. С. 4–9.

16. Abed H., Rahn D.D., Lowenstein L., et al. Incidence and management of graft erosion, wound granulation, and dyspareunia following vaginal prolapse repair with graft materials: a systematic review // *Int Urogynecol J*. 2011. Vol. 22, N 7. P. 789–798.

17. Blandon R.E., Gebhart J.B., Trabuco E.C., Klingele C.J. Complication from vaginally placed mesh in pelvic reconstructive surgery // *Int Urogynecol J*. 2009. Vol. 20, N 5. P. 523–531.

18. Dandolu V., Akiyama M. Mesh complications and failure rates after transvaginal mesh repair compared with abdominal or laparoscopic sacrocolpopexy and to native tissue repair in treating apical prolapse // *Int Urogynecol J*. 2017. Vol. 28, N 2. P. 215–222.

19. Sung V.W., Rogers R.G., Schaffer J.I., et al. Graft use in transvaginal pelvic organ prolapse repair: a systematic review // *Obstet Gynecol*. 2008. Vol. 112, N 5. P. 1131–1142.

20. Ходаков В.В., Забродин В.В., Забродин Е.В., Васёва О.Н. Ближайшие и отдаленные результаты хирургического лечения паховых грыж с применением сетчатых титановых эндопротезов // Медицинский журнал. 2018. № 7. С. 93–101.

DOI: 10.25694/URMJ.2018.04.132

AUTHORS INFO

***Tat'yana V. Gavrilova**, obstetrician-gynecologist;
address: 119435, Moscow,
Russian Federation;
e-mail: gavrilova.tw2010@yandex.ru

Anatoliy I. Ishchenko, MD, Dr. Sci. (Med.), Professor;
ORCID: <https://orcid.org/0000-0003-3338-1113>;
e-mail: 7205502@mail.ru

Anton A. Ishchenko, MD, Cand. Sci. (Med.);
ORCID: <https://orcid.org/0000-0001-6673-3934>;
eLibrary SPIN: 2306-4571;
e-mail: ra2001_2001@mail.ru

Oksana Yu. Gorbenko, MD, Cand. Sci. (Med.);
ORCID: <https://orcid.org/0000-0002-3435-4590>;
eLibrary SPIN 8725-1419; e-mail: go2601@mail.ru

Teya A. Dzhibladze, MD, Dr. Sci. (Med.), Professor;
ORCID: <https://orcid.org/0000-0003-1540-5628>;
e-mail: djiba@bk.ru

Irina D. Khokhlova, MD, Cand. Sci. (Med.);
ORCID: <https://orcid.org/0001-0001-8547-6750>;
e-mail: irhohlova5@gmail.com

Leonid S. Aleksandrov, MD, Dr. Sci. (Med.), Professor;
ORCID: <https://orcid.org/0000-0002-7601-3532>;
eLibrary SPIN: 2738-9662; e-mail: leonid.aleks@bk.ru

ОБ АВТОРАХ

***Гаврилова Татьяна Владимировна**,
врач акушер-гинеколог;
адрес: 119435, г. Москва, Россия;
e-mail: gavrilova.tw2010@yandex.ru

Ищенко Анатолий Иванович, д-р мед. наук, профессор;
ORCID: <https://orcid.org/0000-0003-3338-1113>;
e-mail: 7205502@mail.ru

Ищенко Антон Анатольевич, канд. мед. наук;
ORCID: <https://orcid.org/0000-0001-6673-3934>;
eLibrary SPIN: 2306-4571;
e-mail: ra2001_2001@mail.ru

Горбенко Оксана Юрьевна, канд. мед. наук, доцент;
ORCID: <https://orcid.org/0000-0002-3435-4590>;
eLibrary SPIN 8725-1419; e-mail: go2601@mail.ru

Джибладзе Тея Амирановна, д-р мед. наук, профессор;
ORCID: <https://orcid.org/0000-0003-1540-5628>;
e-mail: djiba@bk.ru

Хохлова Ирина Дмитриевна, канд. мед. наук, доцент;
ORCID: <https://orcid.org/0001-0001-8547-6750>;
e-mail: irhohlova5@gmail.com

Александров Леонид Семёнович, д-р мед. наук, профессор;
ORCID: <https://orcid.org/0000-0002-7601-3532>;
eLibrary SPIN: 2738-9662; e-mail: leonid.aleks@bk.ru